

GASTRO-INTESTINAL FOREIGN BODY SYNDROME IN SHEEP — A CASE REPORT

AKINRINMADE, J.F., AKUSU, M.O. and ONI, S.O.

*Department of Veterinary Surgery and Reproduction
University of Ibadan, Ibadan.*

(Received 15, November 1988; accepted for publication 15 March 1988)

ABSTRACT

A case report of gastro-intestinal foreign body with clinical consequence in sheep is presented. Diagnosis was based on radiography and exploratory laparotomy.

Treatment involved surgical removal via left flank incision under epidural anaesthesia. A review of the aetiopathogenic factors and clinicopathological features of the syndrome in cattle, sheep and goats in Nigeria are also discussed.

Key Words: Gastro-intestinal tract; Foreign body Syndrome, Sheep.

INTRODUCTION

Diseases and disorders of the gastro-intestinal tract (G.I.T.) are commonly encountered in farm animals.

Although a lot of information exists on the severity and grave consequences of GIT disorders in cattle, sheep and goats managed under various systems of husbandry, (Baker, 1979; Sharma and Ranka, 1978; Kline *et al*, 1983; Fatimah *et al*, (1983) there is little or no information on the incidence of GIT foreign body syndrome in ruminants in Nigeria. Therefore the clinical and economic implications of this syndrome are yet to be quantified and fully appreciated.

This paper presents a case report of gastro-intestinal foreign body in a ewe. It also reviews the aetiopathogenesis and clinical features of the syndrome in ruminants in Nigeria.

CASE HISTORY

A 3 year-old Yankasa ewe weighing about 45 kg, was presented to the clinic of the University of Ibadan Veterinary Teaching Hospital, weak, emaciated, depressed and anorexic with distended abdomen. It was reported to have lambed about 8 weeks prior to presentation and was one of a herd of six sheep managed extensively by the owner who resides in Ibadan Municipality.

On presentation, rectal temperature (41°C) was slightly increased while respiratory and pulse rates were within normal range. (12/minute and 74/minute respectively). Upon ballotment, a firm mass was felt in lower distended abdomen. Auscultation revealed increased intensity and frequency in abomasal peristalsis although ruminal contractions were normal. There was no evidence of diarrhoea as pelleted faeces were evacuated from the rectum.

Radiographic examination revealed radiopaque masses in the abdomen, which

were suspected to be foreign bodies. (Fig. 1). A tentative diagnosis of gastro-intestinal foreign body was made and surgical intervention was indicated through rumenotomy.

Surgical Procedure:

After routine surgical preparation of the left flank, the ewe was sedated with xylazine at 0.2 mg/kg body weight, and given epidural anaesthesia by the injection of 5ml of 2% xylocaine into the lumbosacral space combined with local infiltration of the incision line with the same agent.

A 12 cm long dorso-ventral incision was made through the body wall layers on the left flank about 3 cm behind the rib cage and 5 cm below the vertebral column to approach the peritoneal cavity. The foreign masses were located in the abomasum and lower intestine and removed via rumenotomy.

The incision was closed routinely using 2-0. chromic catgut for the body wall layers and monofilament nylon for the skin. Post-operative care consisted of procaine penicillin and streptomycin injection for 3 days.

RESULT

Upon exposure, there was evidence of peritonitis as revealed by several tiny 'milk spots' on peritoneal surfaces and adhesions between the peritoneum and adjacent structures, (Fig. 2).

Systematic exploration and palpation of the entire length of the GIT confirmed the presence of the masses in the abomasum and lower intestine. The masses which were then removed were seen to be firm, hard with concentric circles and containing varying proportions of sand, pebbles, polythene bags, polythene rope, jute bags, twine and other petrochemical by-products (Fig. 3). The total weight of the foreign body was 285.5 gms. No chemical analysis of the mas-

ses was undertaken.

DISCUSSION

Gastro-intestinal foreign body is a disease entity which affects cattle, sheep and goats. Although reports on clinical and fatal cases have not to the best of our knowledge been documented in Nigeria, this case report lends support to its existence in our environment.

The aetiopathogenesis of the syndrome is still poorly understood. Factors so far incriminated appear to vary from place to place and are related to husbandry practises. Fatimah *et al* (1983) reported that ingestion of latex from the tree, *Havaea brasiliensis* is a frequent cause of gastro-intestinal impaction in cattle in rubber growing areas of Malaysia, while ingestion of excessive quantities of poor quality roughage was incriminated by others. (Bakers, 1979; Hoffsis and McGiurk, 1981). Abomasal impaction in sheep following consumption of poor feed has also been documented. (Kline *et al*, 1983; Naerland and Helle, 1962). Imren, (1982) on the other hand incriminated decreased blood concentration of phosphorus in the aetiopathogenesis of foreign body syndrome in cattle.

The aetiological factors in Nigeria may probably be due to inadequate nutrition especially during the dry season; bad husbandry practises particularly in urban areas and vitamin/minerals deficiency often associated with perverted appetites. In this report, determination of blood phosphorus level was not undertaken hence the involvement of phosphorus deficiency as a probable aetiopathogenic factor could not be ascertained.

The observation of gastro-intestinal foreign body in some animals slaughtered at the Ibadan central abattoir further confirms the prevalence of the syndrome in this area, (Idowu, 1988, Personal communication). In

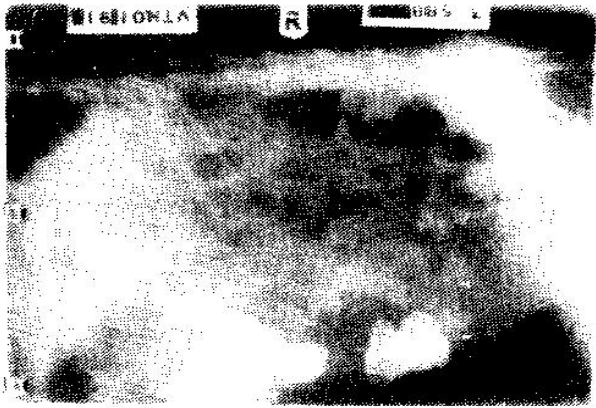


Fig. 1

Lateral radiograph of the abdomen showing radioopaque masses in the abdominal cavity.

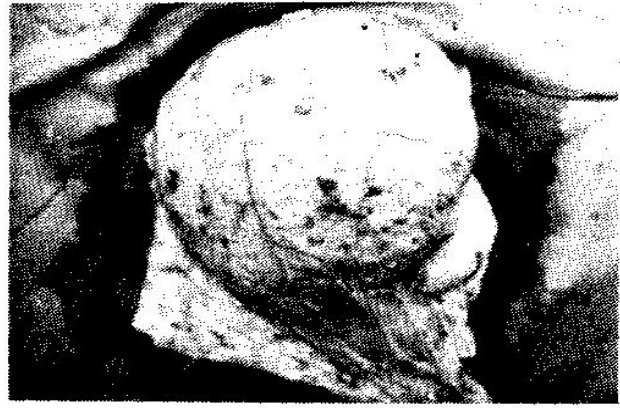

Fig. 2

Photograph of the abomasum showing enlargement and the presence of numerous tiny milk spots — evidence of peritonitis.

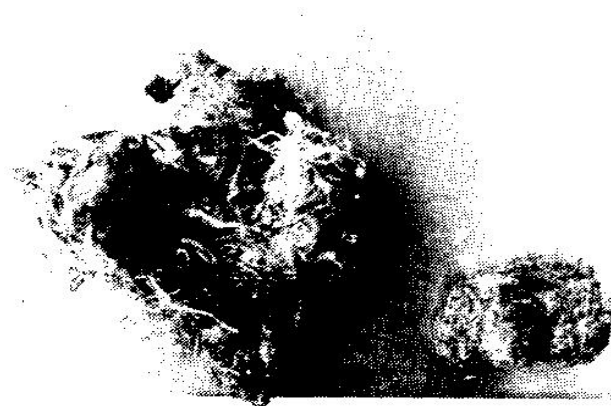


Fig. 3

Photograph of the foreign body after surgical removal.

virtually all the abattoir specimens the foreign masses are similar in gross appearance and macroscopic composition. This probably suggest similarity in aetiopathogenesis. Formation of the observed masses is probably a slow, progressive process accompanied by gradual weight loss, unthriftiness and poor feed utilization.

Peritonitis and peritoneal adhesions were observed to be complications of primary foreign body syndrome.

In conclusion, a better understanding of the aetiopathogenesis of this syndrome in ruminants would require further studies.

ACKNOWLEDGEMENT

The authors are grateful to Dr. A.L. Idowu for his assistance and Mrs. H.I.O. Jegede for typing this manuscript.

REFERENCES

- BARER, J.S. 1979, Abomasal obstruction and related obstructions of the forestomach in cattle. *Journal of the American Vet. Medicine Association* 175 (12) 1250-1253.
- BLOOD, D.C., HENDERSON, J.A. and RADOSTITS, O.M. 1979 *Veterinary Medicine* 5th edition, Lea and Febiger, Philadelphia, p. 194.
- FATIMAH, I, BONGSO, T.A. and LEE J. Y. S. 1983 Latex gastrointestinal impaction in two bulls *veterinary Record*. 113, 89-90.
- HOFFSIS, G. F. and McGUIRK, S. M. 1981, *Current Veterinary Therapy: Food Animal Practice*. Ed. J.L. Howard. W.B. Saunders Co Philadelphia, p. 891.
- IDOWU, A. L. 1988, Personal communication.
- IMREN, H.Y. 1982, changes in blood calcium and phosphorus concentrations in cattle with the foreign body syndrome. *Veterinary Fakultesi Deirgisi, Aukara Universities* 29 71-78.
- KLINE, E.E., MEYER, J. R. and MEMON, M. A. 1983, Abomasal Impaction in sheep. *Veterinary Record* 113, 177-179.
- NAERLAND, G. and HELLE, O. 1962. Functional pyloric stenosis in sheep. *Veterinary Record* 74 (3) 85-90.
- SHARMA, K. B. and RANKA, A. K. 1978. Foreign body syndrome in goats — A case report of 5 cases. *Indian Veterinary Journal* 55 (5) 413-414