

# THE APPLICATION OF THE IMMUNOPEROXIDASE (IP) ANTIBODY TECHNIQUE FOR THE ETIOLOGICAL DIAGNOSIS OF INFECTIOUS BURSAL DISEASE (IBD) IN CHICKENS

E.N. OKEKE\* and G. LANG,  
*Dept. of Vet., Microbiology & Immunology, Ontario Vet. College, University of Guelph, Ontario, Canada.*

## SUMMARY

THE indirect IP — technique was employed in demonstrating sites where IBD antigen reacted with its antibody in IBD-infected bursa of Fabricius. In this, a rabbit — anti-chicken IgG, which was conjugated to horseradish peroxidase, was used as the immunochemical tracers of the antigen-antibody interaction between IBD chicken antiserum and sections of bursa of Fabricius (BF) from IBD infected chickens. The technical details were examined and compared with the immunofluorescent (IF) antibody technique. The IP — technique was simpler to perform, gave permanently stained specimen, and was easier to interpret because it was less subject to background staining than the IF — technique. However both the IP and the IF — techniques were of equal diagnostic sensitivity and specificity.

Some attempts made to use the IP — technique for detecting IBD field virus isolates in cell-culture isolation systems were unsuccessful. The IP — technique was, however, capable of demonstrating cell-culture adapted IBD viruses in cell monolayers.

\*Present Address:— National Veterinary Research Institute, Vom, Plateau State, Nigeria.

## INTRODUCTION

Infectious bursal disease affects mainly chickens 2—6 weeks old. Chicks younger than 2 weeks are often protected from the infection by specific maternal antibodies.

IBD destroys the BF of chickens and may thus inhibit the physiological maturation of the humoral immune system of the young chicken thereby rendering them susceptible to bacterial, fungal and viral infections.

Diagnosis of IBD is usually based on the gross and microscopic pathological changes in the BF. Virus isolation, generally, the best procedure in diagnostic virology, is unfortunately hampered by two difficulties (a) the virus infection is widespread in poultry population (Hitchner, 1971) and antibodies in the yolk will usually prevent the growth of virus in the embryonated egg; thus eggs from specific pathogen free (SPF) supply flocks are required and these are not universally available; (b) to date, there is no cell culture system that permits the routine isolation of field viruses; only a few laboratory adapted strains have been propagated in vitro (Lukert, 1974).

The specific etiological diagnosis of IBD is based on the agar gel precipitin test (AGPT) using high titered bursal extract from acutely diseased chicks and known high titer antiserum.

The viral antigen can also be detected by fluorescent microscopy of bursal sections stained with specific antibodies conjugated to fluorescent dyes. The AGPT is a particularly insensitive technique, which requires a high concentration of antigen that can only be produced from an expensive source, namely the BF of infected SPF chickens.

The IF — technique is at present the specific diagnostic procedure for the routine identification of IBD virus in diseased tissues. However, its application is restricted by the necessity for special and expensive microscopes, by the lability of the IF — reagents and by the impermanence of the stained preparations.

Other labelled antibody techniques have been developed. The IP — technique, especially, has attracted the interest of many because it is simple, stable, and

## IP ANTIBODY TECHNIQUE FOR DIAGNOSIS OF IBD

sensitive (Baba and Yamaguchi 1973; Galenzi and Lunger, 1970). Therefore the intent of this study was: (a) to adapt the IP — technique for the specific diagnosis of IBD, and to compare it with other standard serological tests (IFT,

AGPT and SNT); and (b) to attempt the demonstration of the IBD viral antigen in cell cultures infected with laboratory adapted and unadapted viruses with the aid of labelled antibodies.

### MATERIALS AND METHODS

#### 1. *Virus Strains:*

*The following were used as reference virus strains:*

<b>Virus</b>	<b>Passage History</b>	<b>Reference Source</b>
(a) IBD S.40747	Several Passages in embryonated eggs.	(Ide, 1975)
(b) IBD Sterwin Vaccine	Chick embryo vaccine	—
(c) IBD Georgia	Cell culture origin	(Lukert & Davis 1974)
(d) IBD Becht	Cell culture origin	Originally from Dr. H. Becht W. Germany
(d) IBD Becht	Cell culture origin	Originally from Dr. H. Becht W. Germany.
(e) IBD Van Dijk	Field Isolate from broilers	Dr. C. Van Dijk, Shakespear Ontario, Canada.
(f) Agent 2571	Isolate from a disease condition similar to IBD	Dr. G. Lang. Ontario Vet. College, Canada.

#### 2. *Virus Culture Systems*

The Laboratory Propagation of the virus was as follows

(a) In five week old SPF chickens obtained from the Connaught Laboratories, Toronto. One ml of the virus was given orally and the bursa harvested three days later, mixed with equal volume of PBS,

pH 7.4 and homogenised with a tissue grinder. The homogenate was frozen and thawed five times and clarified at 10,000 rpm for 30 minutes. The clarified supernate was used as antigen in AGP tests.

(b) In 10-day-old chicken embryos (CE) inoculated with the virus by the CAM route and harvested after 3

days incubation at 37°C and homogenized in a Waring blender in four times its volume of PBS, pH 7.4. The homogenate was frozen and thawed five times and centrifuged at 5000 rpm for 30 minutes at 4°C. Further purification was done by homogenizing the supernatant fluid with an equal volume of fluorocarbon (1, 1, 2. Trichlorotrifluoroethane). The two phases were then separated by centrifugation at 10,000 rpm for 30 minutes at 4°C. Fetal calf serum was added to the aqueous phase to a 2% concentration before storage at -70°C.

- (c) In chicken embryo fibroblast (CEF) cell culture inoculated with the virus in suspension before incubation. Complete monolayer was formed within 12–24 hours. Cell culture methods employed were those described by Hitchner (1971).

Monolayer cell cultures of embryo kidney (CEK), bursa (CEB) and liver (CEL) were prepared in a similar manner to CEF monolayers; however, 15% FCS was incorporated into the growth medium in order to facilitate the attachment of the cells to the glass wall (Lukert and Davis, 1971). Only embryos of less than 15 days were used for culture of both CEB and CEL monolayers. Organs of CE older than 15 days did not attach readily to the glassware.

### 3. Serology

- (a) Production of antisera  
Hyperimmunized chickens were bled by cardiac puncture directly into a centrifuge tube. The blood was allowed to clot for two hours and was then centrifuged at 17,000 rpm for 10 minutes at 4°C. The serum was collected and stored at -20°C.
- (b) Agar gel precipitin test (AGPT)

The agar gel precipitin test was conducted as described by Hirai and Shimakura (1972) in 0.15M NaCl for fresh serum or in 1.5M NaCl for aged serum (i.e. serum that has been stored at +4°C -20°C for more than one week) (Kramer and Auburu, 1973).

- (c) Serum Neutralization test (SNT)  
The constant virus varyirus serum lectnque was employed using the tube method (Cunningham 1966; Hitcher 1971; Lennette 1969; and NATL. ACAD. SCIE. 1971) or the Microneutralization test (MNT) as described by Wooley, Brown, Davis, Blue and Lukert (1976).

### 4. Preparation of paraffin Sections of Bursa of Fabricius (BF)

The method described by Sainte-Marie (1962) for the immunofluorescence staining of paraffin embedded tissue sections was employed.

### 5. Preparation of Frozen Sections

The cryostat was precooled to -20°C and the specimen was frozen onto the metal holder. With a sharp knife cooled to the same temperature, sections of a 6 micron thickness were cut, mounted on a microscope slide, air dries and fixed in acetone at -20°C for 20 minutes before staining. The unstained slides were stored at -20°C.

### 6. Handling of cell culture coverslip preparations for staining

Cells cultured on coverslip in Leighton tubes were rinsed in several changes of PBS to remove all serum. The coverslips were air dried then transferred into acetone for 15 minutes to remove the lipids so that antibody and conjugate

## IP ANTIBODY TECHNIQUE FOR DIAGNOSIS OF IBD

could penetrate easily into the tissue. They were finally labelled and stored at  $-20^{\circ}\text{C}$ .

### 7. *Direct and indirect staining methods*

Both the direct and indirect peroxidase staining procedures were used in these studies. In both methods the BF section, or the fixed and labelled convership monolayer, were placed in an airtight box with wet paper towels and glass rods for support. In the direct method the anti BIBD IgG-HRPO conjugate was added to the slides or coverslips for 1 hour at  $37^{\circ}\text{C}$ . In the indirect method the anti IBD serum was first added to the slides or coverslips after which they were rinsed in 8 changes of PBS in individual jars for at least 3 minutes per rinse. The sections or coverslips were then covered with HRPO labelled rabbit anti-chicken IgG and incubated again in a humidified box for 1 hour at  $37^{\circ}\text{C}$ .

Hereafter the treatment was the same for both the direct and indirect methods; namely, the conjugated was rinsed in three changes of PBS. The PBS was drained and the slide was placed in the developing solution for 10 minutes. This was followed by three rinses in sucrose phosphate buffer, dehydration through grades of 50%, 70%, 95% and absolute ethanol, clearing in xylene and mounting in DPX mountant.

## RESULTS

### 1. *Staining of BF Sections*

Frozen sections of BF stained by the indirect IP — test and the indirect IF — test showed numerous cells with brown reaction products or fluorescence respectively. In most cases the cell outline was indistinct and it was difficult relating to

the exact position of the stained cells with the surrounding tissue components.

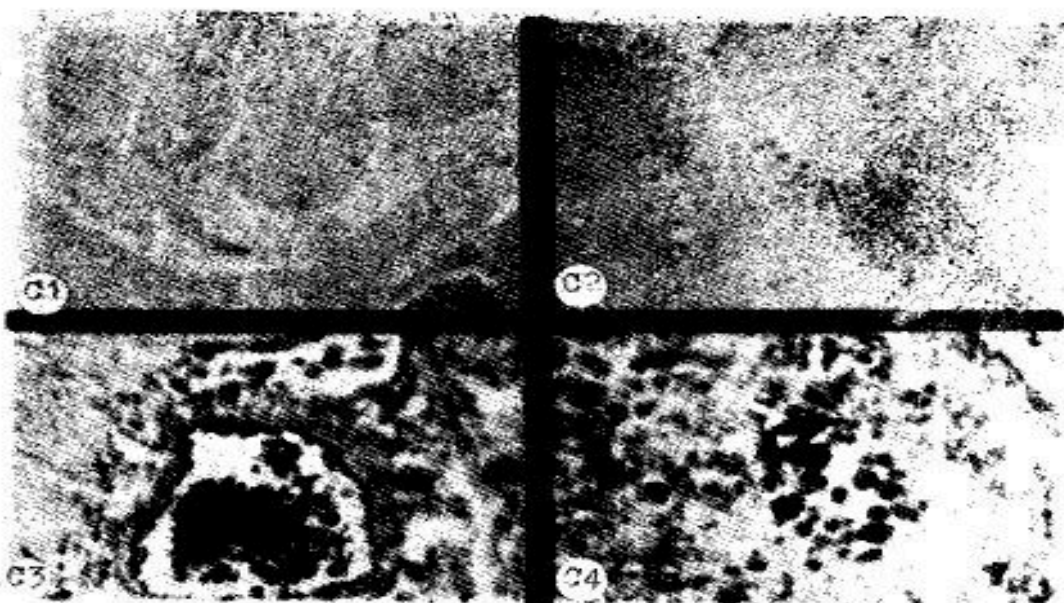
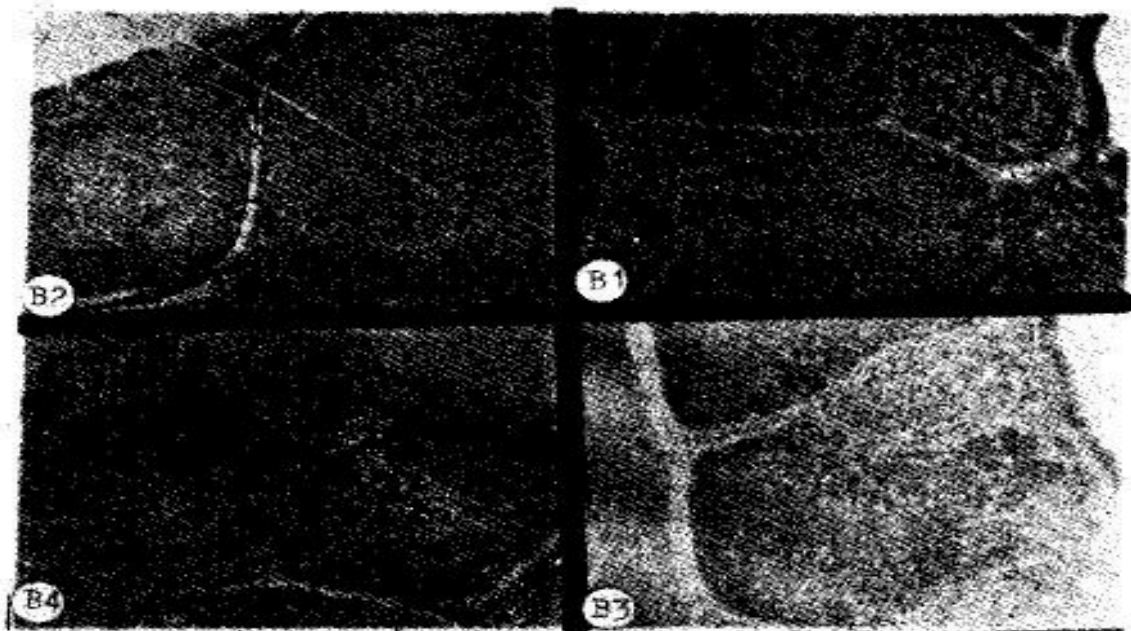
Paraffin sections of the infected BF produced by the method described by Sainte-Marie (1962) preserved the viral antigens so that they could easily be demonstrated in infected cells both by IP — and IF test. With IP method it was observed that the brown reaction product was restricted to the cytoplasm of infected cells and the accurate position of the infected cell in relation to the other tissue components could be observed.

Plate B1 is the normal BF section stained by H & E. Plate B2 depicts the section of a normal uninfected chicken BF stained by IPT. The cells stained in a uniform light brown pattern but without accumulations of dark brown precipitated reaction products of the enzyme and DAB substrate.


Plate B3 is a section of IBD S.40747 infected BF examined on PID — 2, stained by H & E. Plate B4 on the other hand, is the section of an IBD S.40747 infected BF, sampled on PID-2 and stained by IPT. Scattered individual cells showing intensive browning could be seen especially in the cortex of the infected follicle. The medulla was in some cases infected before the cortex, but wherever the infection appeared first, the viral antigen spread invariably throughout the medulla.

Plate C1 is a section of S.40747 infected BF examined on PID-3, stained by H & E. Plates C2, C3 and C4 are sections of BF sampled on PID-3 and stained by IPT. In plate C3 can be seen a large vacuole in the centre of which are large masses of debris of necrotic lymphocytes that stained very darkly because of a high content of viral antigens. Vacuoles such as these were very common in other similar sections examined. In C2 infected cells were still restricted to the medulla.

Plate D1 is a section of BF infected with IBD S.40747 and examined on PID-4



## IP ANTIBODY TECHNIQUE FOR DIAGNOSIS OF IBD



stained with H & E. Plates D2, D3, D4 and D5 are sections of IBD S.40747 infected bursae, sampled on PID-4 and stained by IPT. In D3 the infected cells were still restricted within the medulla, whereas in D4 the vacuoles were prominent and the follicle on the bottom could be seen to have developed a vacuole that contained large numbers of dark-brown staining necrotic lymphocytes. What could be regarded as phagocytic mononuclear cells were also seen and stained dark brown and could be seen scattered within the magnification (600x) as in plates D2 and D5, the intramedullary brown staining cells appear like macrophages that have engulfed some infected lymphocytes.

Plate E1 is a BF section infected with IBD S.40747 as examined on PID-5 and stained by H & E. Plate E2 is the section of an IBD S.40747 infected BF sampled on PID-5 and stained by IPT. Only a few follicles showed dark brown staining macrophages. These were only demonstrable in small numbers suggesting that only very few cells still contained the viral antigen.

Plate E3 is the section of an IBD S.40747 infected BF, sampled on PID-5, stained by the indirect IPT, but a reference negative chicken serum was employed instead of the reference anti-IBD virus positive chicken serum. Antisera adsorbed with high titered IBD virus antigen (BF homogenate as used in AGP test) also showed the same negative staining reaction.

Plate F2 is a section of a BF on PID-2 and Plate F4 the same as sampled on PID-3 from chickens infected with Agent 2571. Both sections were stained by the indirect IP technique with anti 2571 serum. On PID-2, scattered lymphocytes with dark brown staining cytoplasm can be seen, and on PID-3, this aspect was more pronounced, with a greater number of stained and pyknotic cells. Control experiments carried out in parallel with the

above but with anti-IBD serum, did not show any dark staining foci in the sections.

Another control experiment is presented in Plate F5, an Agent 2571 infected BF section, sampled on PID-3 was stained with normal chicken serum. The appearance of the stained preparation is identical to the control experiment cited above. Plates F1 and F3 are stained with H & E.

The inverse test disposition was also tried, in which IBD infected BF was stained with anti Agent 2571 serum; no dark staining was produced in the section. Similar precipitation reactions are seen in Plates G1, G2 & G3 which are sections of BF infected with IBD Becht. The nuclei are non-staining and are surrounded by dark staining cytoplasm.

## 2. *Staining of Cell Cultures*

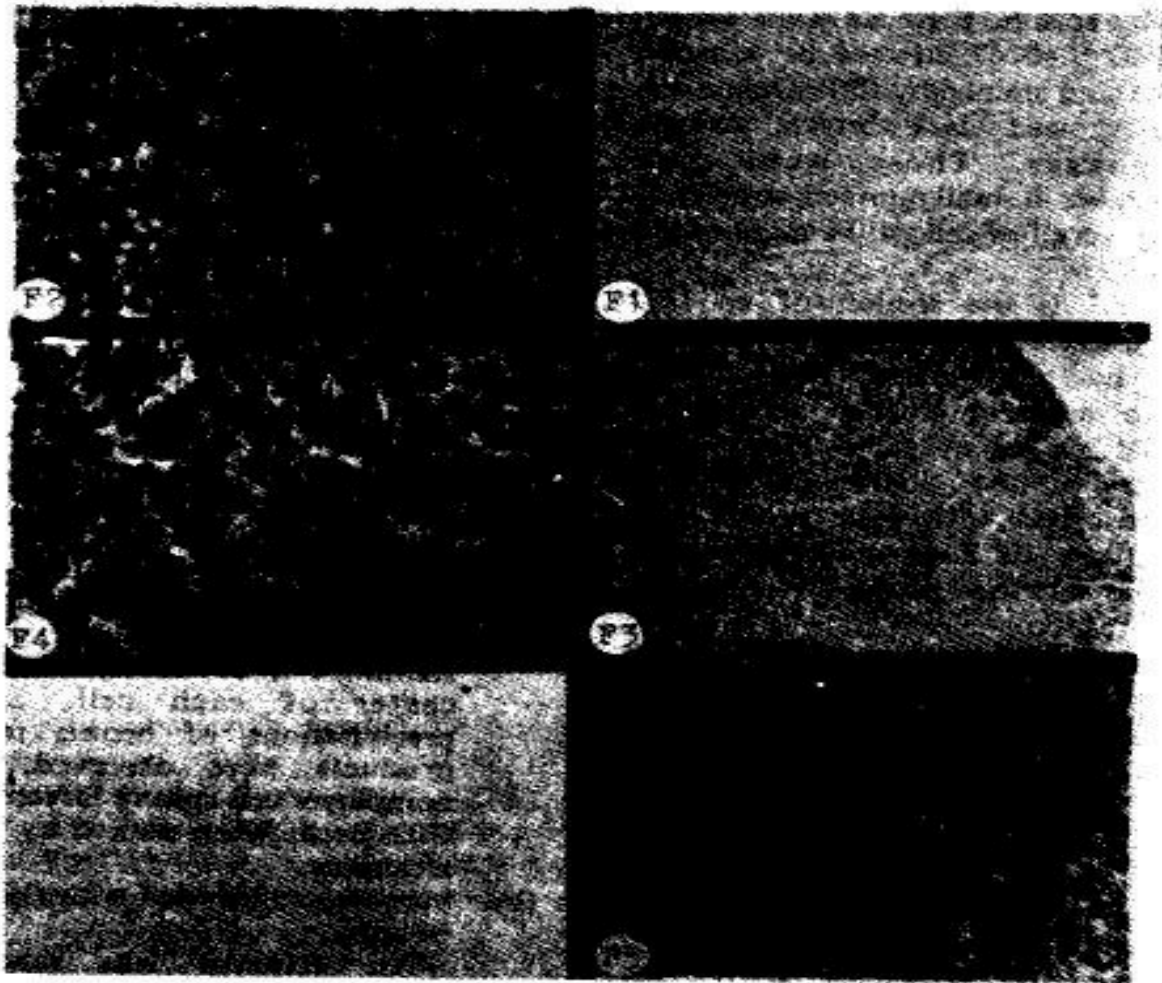

### (a) Monolayers infected with cell-culture adapted IBD virus strains.


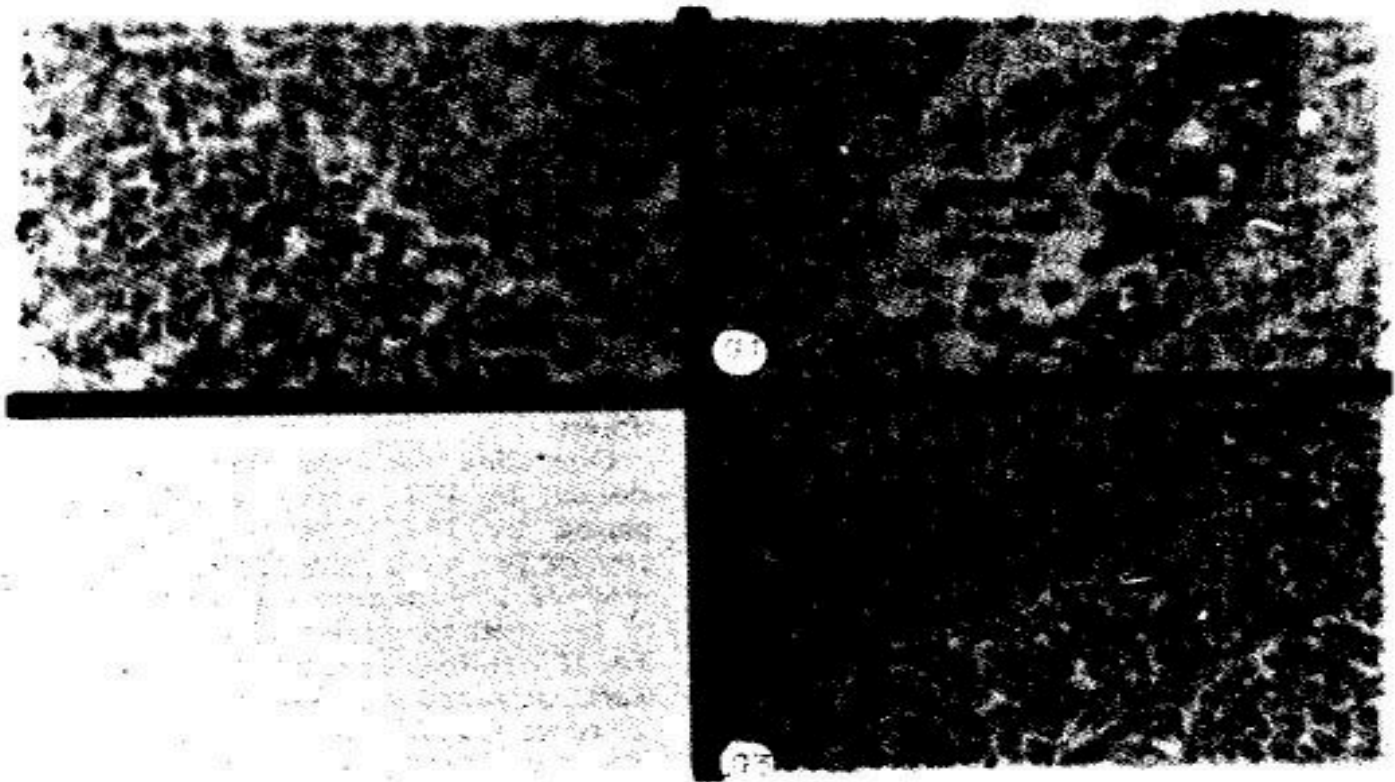
Plate H1 is the normal uninfected CEF monolayer stained with H & E. Plate H2 is an IBD Georgia T. infected CEF monolayer stained by H & E on PID-2. The viral CPE is evident and many of the cells had detached from the coverslips, and the undetached cells appear granular and pyknotic. A parallel infected monolayer stained by IPT is shown in Plate H3. The necrotic cells could clearly be seen and the brown granular reaction products were deposited strictly within the cytoplasm. The nuclei is non-staining oval or rounded area in the center of each cell. Similar precipitations of brown reaction products were observed, when monolayer cell culture infected with IBD Becht were stained by the IP technique.

### (b) Monolayers infected with field IBD isolates.

An attempt was made to demonstrate propagation of field

**IP ANTIBODY TECHNIQUE FOR DIAGNOSIS OF IBD**





## IP ANTIBODY TECHNIQUE FOR DIAGNOSIS OF IBD

IBD virus isolates in CE — monolayers by IPT. The monolayers were inoculated with the BF extract of chickens infected with IBD Van Dijk and IBD S.40747 and incubated at 37°C for 2-3 days before staining. Parallel cultures were passaged on the fourth day after infection for at least three times in each of CE-fibroblast, CE-liver, CE-Kidney and CE-bursal cell culture monolayers and the coverslip stained in each case by IPT. No dark-brown staining sites could be demonstrated and CPE was absent suggesting that this field IBD virus strains did not replicate in cell culture monolayers as did the cell culture adapted strains.

### 3. *Comparison of the Direct & Indirect Immunoperoxidase Staining*

#### *Methods*

The direct IPT with chicken IgG — HRPO conjugate was as intensely staining as the indirect IPT with rabbit IgG — HRPO conjugate. The conjugate for the indirect method could be employed at a dilution of up to 1:16 without any decline in intensity, whereas the conjugate for the direct method could not be diluted beyond 1:2.

### 4. *Comparison of Staining by the Immunoperoxidase & Immunofluorescent Techniques*

Chicken embryo liver (CE) cell cultures were prepared on coverslips in Leighton tubes. These were incubated at 37°C until monolayers had formed. The inoculum consisted of 0.2ml volume of 1000 TCID<sub>50</sub> of Agent 2571. The inoculated monolayers were incubated again at 37°C except for four coverslips that were

removed immediately after a 30 minutes adsorption period. These were washed thrice in PBS, air dried, fixed in acetone for 15 minutes and stored at -20°C and used as zero reading (Hanon, Simpson and Eckert 1975). Thereafter, four slides were removed from the incubator every 2 hours for the first 12 hours and treated in the same way as described for the zero sample. The last eight infected slides were removed 24 hours after incubation, treated as others and stored at -20°C. Four uninoculated slides were left as controls but treated in the same way as the others.

One slide for each time period was stained by IFT, and one of the same period by IPT. The rest of infected coverslips were stored at -20°C as reserves. IFT staining was done according to the method employed by Ide (1975). The IFT stained coverslip cell monolayers were examined with a Zeiss fluorescence microscope equipped with a BG 3 exciter filter and 50/44 barrier filters. The same microscope with an ordinary light source was used to examine IPT-stained cell.

The number of infected cells observed after 0, 2, 4, 6, 8, 10, 12 and 24 hours incubation of coverslips and after staining with IPT and IFT are graphically depicted in Figure 1. The IPT appears to be more sensitive in detecting early infected cells. The IFT did not help in detecting any viral infected cell until the sixth hour when just under 100 cells per 100 microscopic fields were recorded. Thereafter as many infected cells could be detected by IFT as by IPT until the 24th hour when the number of infected cells rose to more than 10,000 per 100 microscopic fields. After 24 hours infected cells were so numerous that counting became impossible

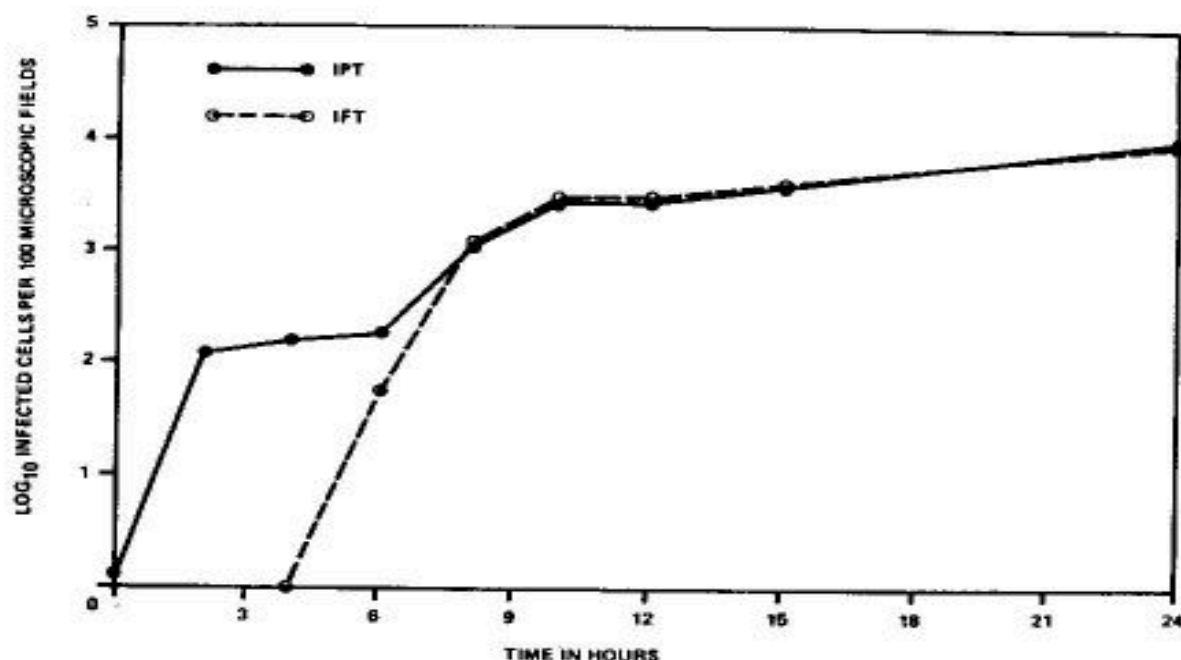


FIG 1: RATE OF INCREASE OF INFECTED CELLS (PER 100 MICROSCOPIC FIELDS) AS DEMONSTRATED BY IFT AND IPT IN CHICKEN EMBRYO LIVER (CEL) MONOLAYERS INFECTED WITH AGENT-2571.

## DISCUSSIONS

The diagnosis of IBD on pathological criteria alone assumes that only IBD virus can cause a gelatinous, oedematous swelling, necrosis of the bursal follicles and finally atrophy of the organ.

So far, these acute bursal lesions are considered pathognomic, if found, but they are ephemeral (from 3-6 days after infection) and the subsequent atrophy of the bursa must be distinguished from atrophy caused by inclusion body hepatitis (Hitchner, 1971), by Marek's disease (Jakowski, Fredrickson, Lunginbuhl and Helenboldt, 1969) or by other causes.

The etiological diagnosis of IBD not easily made. The agar gel precipitin test (AGPT) requires a potent virus antigen, which is best prepared from infected bursa and should be free from other antigens that might interfere with the exact diagnosis. In actual fact SPF chickens ought to be used for the preparation of both the IBD antigen and antiserum which raises the diagnosis of IBD by AGPT to the same level of difficulty as the isolation of the virus in chicken em-

bryos, since SPF chicken flocks are not easily available to poultry diagnosticians. The AGPT and pathological diagnosis are only applicable to the early phases of IBD.

The present experimental observations confirm those of Ide (1975) which show that the maximum antigen titer in the bursa may be expected on the third day of the infection, the time span of reactivity extending only from the second to the fourth days after infection.

This study shows that the fluorescent antibody (FA) staining has greater sensitivity than AGPT, and in the specific instance of IBD, the virus can be demonstrated in the bursa from the second to the fifth days of the infection. Cheville (1967) and Ide (1975) could detect the specific IBD virus antigen in bursae until PID-6; Valdes (cited in Ide, 1975), PID-9 and Adrusbali and Gialletti (cited in Ide 1975) until PID-10. In none of these studies, however, did the FA staining equal the diagnostic sensitivity of virus isolation from bursa tissue, which in Ide's experiments, was still positive at PID-14 but not on PID-21.

## IP ANTIBODY TECHNIQUE FOR DIAGNOSIS OF IBD

It is against this background that the performance of the IP-test has to be viewed. Since the enzyme test is based only on a kinetic chemical reaction, but the FA-test is in addition heavily dependent on fluorescence which is a static physical phenomenon, the former should have a greater sensitivity than the latter. And since there is IBD virus in the bursa of the chicken beyond the time of detectability by FA, it could be expected that the IP-test would reveal the virus antigen for a longer time. This expectation was not borne out in our investigations, the IP-test having a sensitivity equal to the FA-test. However, the IP-test was more sensitive than the FA test in detecting early viral antigens in cell culture (Fig. 1).

The suggestion that all field IBD virus isolates could be propagated in cell culture monolayers (Lukert and Davis 1974) prompted a further investigation into this matter and the use of IP-staining to demonstrate viral antigens in culture, especially where no CPE was demonstrable. This approach was unsuccessful. The reason for this is not clear. The propagation of IBD field viruses in cell culture is not easily accomplished. Shimizu and Tonizawa (1970) attempted without success to propagate the virus in CE Kidney cell cultures; Lukert and Davis (1974) required four serial passages in CE bursa cells before their virus strain could be grown in CE-Kidney cell culture. Gelenzei and Lunger (1970), Kusters and Paulsen (1971) Landgraf, Vielitz and Kirsch (1967) and Mora (1966) have all successfully adapted IBD viruses to cell cultures, but these authors often referred to IBD virus as a reovirus, a taxonomic affiliation questioned recently by Harkness, Alexander, Pattison and Scott (1975) and Nick, Cursiefen and Becht (1976). True avian reoviruses or similar agents can be isolated from the avian bursa, as is evident from the reovirus contaminating the Georgia cell culture adapted virus received from Dr. Lukert, and by the number of falsely labelled "IBD" viruses with which this investigation was started. The IP-staining can be used to study the factors that permit the

cell culture adaptation of IBD viruses as is the case with the two adapted IBD strains, Georgia and Becht. The viral antigen appeared in these cultures as fine granular, dark-brown material within the cytoplasm.

Besides the wide operational margins in the technical requirements for IP-staining, the enzyme test has several other advantages over the FA technique:

- (i) The commercially available horseradish peroxidase is available from several sources and in a form pure enough ( $RZ = 3.0$ ) for the coupling procedure, which in itself is a simple procedure that can be carried out with minimal equipment by personnel with only a basic understanding in biochemical procedures;
- (ii) The IP-stained preparations can be viewed under standard optical microscopes, whereas the fluochrome — labelled antibodies can be observed only under a special microscope that very few laboratories can afford to possess;
- (iii) The IP-stained preparations are stable, and can be preserved as permanent records or as standards — for comparison. FA-stained specimens are ephemeral preparations that tend to fade under the ultraviolet light beam, and photographic records must be made for permanent documentation;
- (iv) The IP-test equals, or excels, the FA method in diagnostic sensitivity. The presence of peroxidasic enzymes in the tissue is far less frequent and annoying in the IP-test than is autofluorescence in the FA method.

In the particular instance considered here, IBD bursa sections offered no problem by endogenous peroxidase, whereas the latter was very apparent in spleen sections, where non-specific dark brown deposits were diffuse and amorphous in contrast to the specific viral antigenic sites of sharply defined dark-brown fine granulations. Incorporation into the

issue fixative of anti-peroxidase substances, such as methanol, ethanol, hydrochloric or acetic acid, or sodium nitrofericyanide as advocated by others (Straus 1964; Streefkerk, 1972; Weir 1974) was not necessary with the BF tissue. Cell culture preparations were entirely free of endogenous peroxidases. One slight disadvantage remains with the use of DAB in the IP-test: viz: benzidine is carcinogenic and should be manipulated with caution (Benjamin 1975). The risk should be minimal if adsorption or direct contact of the drug with the skin is avoided, and the used chemical is properly disposed.

This study on IBD has also revealed the value of cell culture-adapted IBD viruses for serodiagnosis and virus identification. Surprisingly serum-neutralizing titers were detectable in convalescent sera against 100 TCID<sub>50</sub> of virus. Furthermore the SN-test permitted the elimination from the study of the "false IBD virus" isolates that complicated the initial phase of the investigation. Agent 2571 was one of these mislabelled viruses prominently displayed here because the preliminary experiments were done with it until the cell culture adapted IBD viruses could be obtained. However cross-tests with virus 2571 and with the Fahey Crawley avian reovirus proved the serological individuality of the IBD virus group. The SN-test also showed the close serological similarity of the European (IBD Becht) and the North American isolates (S.40747, Van Dijk, and sterwin vaccine). The SN-test is far more sensitive than the agar gel diffusion test and merits prime consideration in the diagnosis of IBD.

REFERENCES

BABA, T. N. YAMAGUCHI, R. ISHIDA & I. SUZUKI (1973): Ultra-structural localization of T-antigen in SV40 transformed Kidney cells of a green monkey by the peroxidase labelled antibody method. *Gann.* **64**: 173 — 177.  
 BENJAMIN, D.R. (1975): Use of immunoperoxidase for rapid viral diagnosis. *Microbiology* 1975, pp. 89 — 96. American Society for Microbiology.

BERENBAUM, M.D. (1959): The autoradiographic localization of intracellular antibody. *Immunology* **2**: 71 — 83.  
 CHEVILLE, N.F. (1967): Studies on the pathogenesis of Gumboro disease in the bursa of Fabricius spleen and thymus of the chicken. *Am. J. Path.* **51**: 527 — 551.  
 COSGRAVE, A.S. (1963): An apparently new disease of chickens — Avian nephrosis. *Avian Dis.* **6**: 385.  
 CUNNINGHAM, C.H. (1966): *A Laboratory Guide in Virology* 6th Ed. Burgess Publishing Co., Minneapolis, Minnesota.  
 GELENZEI, E.F. and P.D. LUNGER (1970): Isolation of a reovirus from bursa of Fabricius of chickens affected by infectious bursal disease. *J. An. Vet. Med. Ass.* **156**: 1270 — 1271.  
 GIRARDI, A.B. H AMPER, K.C. HDU, R. HORRIBERGER, G. KELLOFF and R.V. GILDEN (1973): Intracellular localization of mammalian type C virus species-specific (gs-1) and inter-species specific (gs-3) antigenic determinants with the indirect immunoperoxidase technique and light microscopy. *J. Immunol.* **111**: 152 — 156  
 GRAHAM, R.C. & M.J. KARNOVSKY (1966): Glomerular permeability. Ultrastructural cytochemical studies using peroxidase as protein tracers. *J. Exp. Med.* **124**: 1123.  
 HANON, N.J. SIMPSON, H.L. ECKERT (1975): Assessment of virus infectivity by the Immunofluorescent and Immunoperoxidase techniques. *J. Clin. Microbiol.* **1**: 324 — 329.  
 HARKNERS, J.W., D.I. ALEXANDER, M. PATTISON & A.C. SCOTT (1975): Infectious bursal disease agent: Morphology by negative stain electron microscopy. *Archives of Virology* **48**: 63 — 73.  
 HIRAI, K. & S. SHIMAKURA (1972): Immunodiffusion reaction to avian infectious bursal virus. *Avian Dis.* **16**: 961 — 964.  
 HIRAI, K. S. SHIMAKURA, C.N. CHANG, Y. ADACHI, E. KAWAMOTO, N. TAGUCHI, Y. SUZUKI, C. ITAKURA, F. FUNALASHI, Y. TSUSHIO & M. HIROSE (1973): Isolation of infectious bursal disease virus and distribution of precipitating antibodies in chicken sera. *Jap. J. Vet. Sci.* **35**: 61 — 70.  
 HITCHNER, S.B. (1971): Persistence of parental infectious bursal disease antibody and its effect on susceptibility of young chickens. *Avian Dis.* **15**: 894 — 900.  
 IDE, P. R. (1975): A comparison of gel diffusion, fluorescent antibody and virus isolation methods in experimental and Comp. Med. **39**: 183 — 190.  
 JAKOWSKI, R.M., T.N. FREDRICKSON, R.E. LUGINBUHL and C.F. HELENBOLDT (1969): Early changes in bursa of Fabricius from Marek's Disease. *Avian Dis.* **13**: 215 — 222.  
 KRAMER, T.T., A AUBURU (1973): Immunologic response of birds. *Avian Dis.* **17**: 207 — 213.  
 KOSTERS, J. & PAULSEN, J. (1971): Ver mehrung des Erregers der Infektiosen Bursitis der Junghennen

## IP ANTIBODY TECHNIQUE FOR DIAGNOSIS OF IBD

- (Gumboro Krankheit) in Hühnerembryonizellkultur. *Zentbl. Vet. Med.* **18B**: 366-372.
- LANDGRAF, H.E. VIELITZ & R. KIRSCH (1967): Untersuchungen über das Auftreten einer infektiösen Erkrankung mit Beteiligung der bursa Fabricii (Gumboro disease). *Dt. tierärztl. Wochr.* **74**: 6 — 10.
- LENNETTE, E.H. (1969): "Diagnostic Procedures for viral and Rickettsial infections" 4th Ed. E.H. Lennette and N.J. Schimdt, eds., Am. Pub. Hlth. Assoc., N.Y.
- LUKERT, P.D., & R.B. DAVIS (1974): Infectious bursal disease virus: Growth and characterization in cell cultures. *Avian Dis.* **18**: 243—250.
- LYR, H., (1957): Ein neues Peroxydase Bestimmungsverfahren *Biochem. Z.* **329**:91.
- MORA, E.C., (1966): Virus infections of cultured macrophages and lymphocytes. *Poult. Sci.* **45**: 1106—1107.
- NAKANE, P.K. and K. YASUDA (1975): Recent progress with peroxidase — labelled antibody method. *Acta Histochem. Cytochem.* **8**: 30—39.
- NATL. ACAD. SCIE. (1971): Methods for examination poultry biologics and for identifying and quantifying avian pathogens. *Natl. Acad. Sci., Washington, D.C.*
- NICK, H.D., CURSIEFFEN & H. BECHT (1976): Structural and growth characteristics of infectious bursal disease virus. *J. Virol.* **18**: 227—234.
- PETEK, N., P.N., DAPRILE and F. CANCELLOTTI (1973): Biological and physiochemical properties of the infectious bursal disease. *Avian Pathol.* **2**: 135—152.
- SAINTE — MARIE (1962): A Paraffin embedding technique for studies employed immunofluorescence. *J. Histochem. Cytochem.* **10**: 250—256.
- SHIMUZU, F., M. SHIMUZU, and M. TOMIZAWA (1970): Interfering factor in chicken tissues infected with infectious bursal agent against Western Equine Encephalomyelitis virus. *Natn. Inst. Anim. Hlth. Qt., Tokyo* **10**: 92—93.
- STRAUS, W. (1964): Factors affecting the cytochemical reaction of peroxidase with benzidine and the stability of the new reaction product. *J. Histochem. Cytochem.* **12**: 462—469.
- STREEFKERK, J.G. (1972): Inhibition of erythrocyte Pseudoperoxidase activity by treatment with hydrogen peroxide following methanol. *J. Histochem. Cytochem.* **20**: 829.
- WIR, E.C., T.G. PRETLOW, A. PITTS and E.E. WILLIAMS (1974): A more sensitive and specific histochemical peroxidase stain for the localization of cellular antigen by the enzyme antibody conjugate method. *J. Histochem. Cytochem.* **22**: 1135—1140.
- WEIR, E.E., T.G. PRELOW II, A. PITTS and E.E. WILLIAMS (1974): Destruction of endogenous peroxidase activity in order to locate cellular antigens by peroxidase — labelled antibodies. *J. Histochem. Cytochem.* **22**: 51—54.
- WOOLEY, R.E.J., BROWN, R.B., DAVIS, J.L., BLUE & P.D. LUKERT (1976): Comparison of a microneutralization test in cell culture and virus neutralization test in embryonated eggs for determining infectious bronchitis antibodies, *J. Clin. Microbiol.* **3**: 149—156.