

A case of gastric ulcers and intussusception due to Ascariasis in a 4-months old American Hampshire boar in Sabon Gari Local Government Area, Kaduna State, Nigeria

^{1*}Danbirni, S., ²Nenshi, N. P., ³Daudu, B. B., ⁴Pewan, S. B. and ¹Sackey, A. K. B.

¹Department of Veterinary Medicine, Ahmadu Bello University, Zaria, Nigeria

²Department of Veterinary Pathology, Ahmadu Bello University, Zaria, Nigeria

³Epidemiology Unit, Vet. Services Division, Min. of Agric. Jalingo, Taraba State, Nigeria

⁴National Veterinary Research Institute, Vom, Plateau State, Nigeria



*Corresponding Author: drdanbirni07@yahoo.com

Abstract

A Four months old American Hampshire boar weighing about 35kg from a back-yard piggery in Sabon Gari Local Government Area, Kaduna State was presented with the chief complains of restlessness, shivering and pasty perineum. There was no medical history. Physical examination revealed, pale ocular mucus membrane, restlessness, shivering and pasty perineum. The vital parameters were above normal ranges. Faecal sample from the rectum was taken to the helminthology laboratory of the Veterinary Teaching Hospital, Ahmadu Bello University, Zaria, for helminth egg detection and identification. Based on the tentative diagnosis of Ascariasis and enteritis, 35mg of a 17% piperazine adipate solution and 700mg of a 20% oxytetracycline long acting were administered orally and deep intramuscularly, respectively as single doses. The boar died 2 hours after therapy. Post-mortem examination revealed; distended ingesta-filled stomach, ulceration of the stomach mucosal wall with tarry (blackish) haemorrhages, *Ascaris suum* in the stomach and small intestine, intussusception of the small intestine and empty distal portion of the intussuscepted small intestine. The helminthology laboratory result indicated eggs of *Ascaris suum*. Based on the helminthology laboratory result and the post mortem examination findings, it was concluded that the boar died of gastric ulcer and small intestine intussusception due to Ascariasis. Routine deworming and deworming record keeping in order to know when the next deworming is due were advocated to the farmer.

Keywords: American Hampshire Boar, intussusception, Gastric ulcer, Ascariasis, Piperazine, Sabon Gari LGA

Introduction

Pork is the most widely consumed meat in the world, followed by poultry, beef, and mutton (Worldwatch Institute, 2018). *Ascaris suum* is the most common gastrointestinal parasites affecting pig production in Nigeria aside infectious diseases (Igbokwe and Maduka, 2018). *Ascaris* is a genus of parasitic nematodes that can cause infections in pigs and humans (Miller *et al.*, 2015). Goeze described *Ascaris* helminth for the first time in 1782 and based on morphology, called it *Ascaris suum* (Loreille and Boucher, 2003). *Ascaris*

helminths are important zoonotic pathogens whose eggs are quite resistant to environmental degradation and disinfectants and can remain infective for years although it can be destroyed by intensive steam cleaning or prolonged exposure to full sunlight (Miller *et al.*, 2015). *Ascaris suum* eggs are extremely hardy and can survive for as long as 15 years in the environment (Muller, 1953; Krasnonos, 1978; O'Lorcain and Holland, 2000). They remain viable in swine effluent water for at least 14 months (ISU, 2018). Infested pigs, insects, fomites, blowing

A case of gastric ulcers and intussusception due to Ascariasis

dust, pig manure and effluent, can transport the eggs of *Ascaris suum* to the uninfested locations to infest other stocks (ISU, 2018). Ascariasis is the infestation of swine by the roundworm, *Ascaris suum* and other species as well, when infective eggs are ingested by the swine (Dold and Holland, 2011). All ages of pigs are affected but ascariasis is more severe in young and growing pigs. It is the most prevalent and most economically important internal parasite of swine (Stewart and Hoyt, 2006). The worm is responsible for significant economic losses which include reduction in production efficiency (Stephenson *et al.*, 2980; Hale *et al.*, 1985), liver condemnation at slaughter due to pathology produced by migration of the *Ascaris suum* larval stages (Hale *et al.*, 1985; Loreille and Bouchet, 2003). It is notable to note that *Ascaris suum* has been shown to cause visceral larva migrans in humans and pigs, allergic enteritis and intestinal obstruction in pigs, alongside other complications (Saka-kibara *et al.*, 2002; Stewart and Hoyt, 2006; Karanja *et al.*, 2011). Once a piggery is infested, ascariasis persists in the pig population despite all measures used to eliminate it (ISU, 2018). The extremely high number of eggs that are produced, the resistance of eggs to environmental degradation, and the multiple means in which they can be disseminated contribute to their persistence in infected pig population (ISU, 2018).

Low levels of ascarid exposure stimulate a protective immunity (ISU, 2018). The most severe consequence of ascarid infection occurs when immunologically naïve pigs are placed in contaminated sites. Farrowing and nursery facilities often have a low prevalence of ascarid egg contamination such that young pigs will have had little or no exposure to the parasite and as such these animals are at risk of severe disease when

subsequently placed in contaminated finishing barns (ISU, 2018).

Case presentation

A Four months old American Hampshire boar weighing about 35kg from a back yard piggery in Samaru, Sabon Gari Local Government Area (LGA), Kaduna State was presented with the chief complaints of restlessness, shivering and pasty perineum. There was no medical history. The boar was housed in a concrete floor pen along with an apparently healthy gilt of the same breed and managed under intensive system.

The work plan was to carry out a physical examination on the young boar, collect faecal sample for helminth egg detection and identification and to manage the case accordingly. Respiratory rate was observed from a distance to be rapid. On close physical examination after physical restraint, the rectal temperature was 40.5°C and the pulse rate was rapid. Other clinical signs observed were pale ocular mucus membrane, restlessness, shivering and pasty perineum. The live body weight was estimated at 35kg using a pig-weighing band. Based on the clinical signs and lack of routine deworming history, a tentative diagnosis of Ascariasis and enteritis were made.

Sample collection and case Management

Rectal faecal sample was collected and taken to the helminthology laboratory of the Veterinary Teaching Hospital, Ahmadu Bello University, Zaria, for egg floatation, detection and identification.

Based on the tentative diagnosis of Ascariasis and enteritis, 35mg of 17% piperazine adipate solution at 1mg/kg body weight and 700mg of 20% oxytetracycline long acting at 20mg/kg body weight were administered orally and deep intramuscular respectively as single doses. However, the boar died 2 hours after therapy (Plate 1).

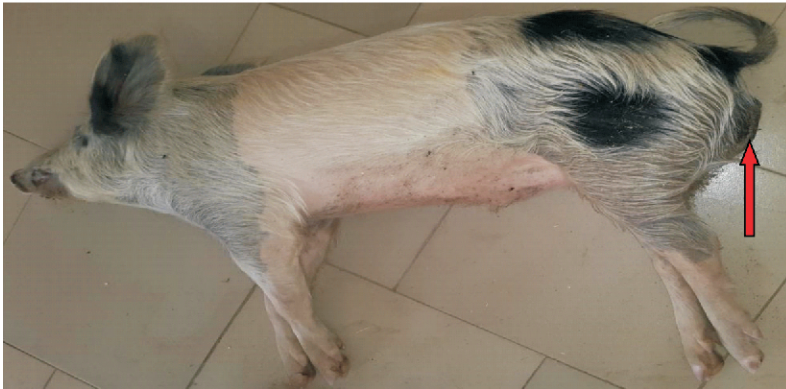

Plate 1: Carcass of a Four months old American Hampshire boar with matted perinium

Post-mortem examination and final diagnosis

Post-mortem examination was carried out by the Necropsy Unit of the Veterinary Teaching Hospital, Ahmadu Bello University, Zaria and the findings were: Grossly distended stomach (Plate 2), ulceration of the stomach

mucosal lining along with tarry (blackish) haemorrhages (Plate 3), *Ascaris* spp. in the stomach and small intestine (Plates 4 and 5), intussusception of the small intestine and empty distal portion of the intussuscepted small intestine (Plate 5). The helminthology laboratory examination of the faecal sample indicated eggs of *Ascaris suum*.

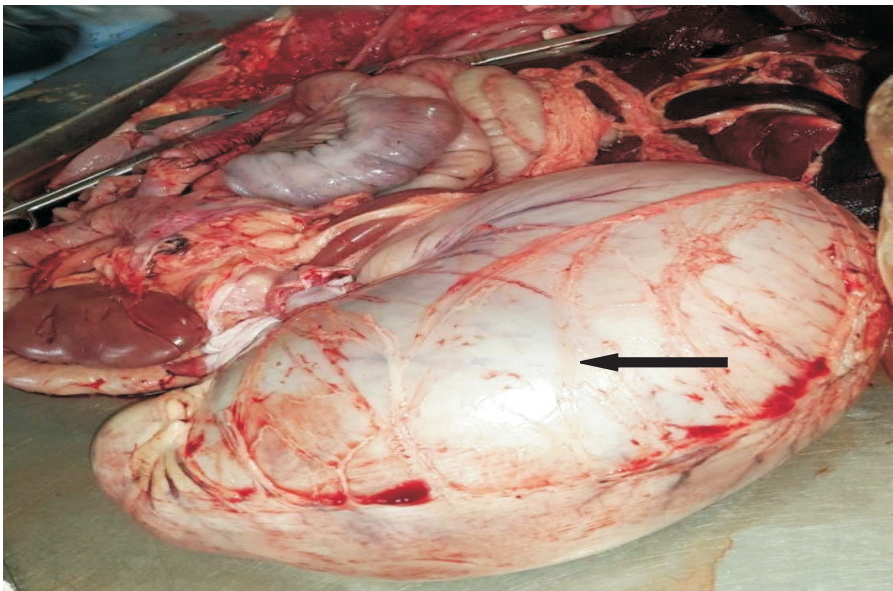


Plate 2: Grossly distended stomach carcass of a Four months old American hampshire boar

A case of gastric ulcers and intussusception due to Ascariasis

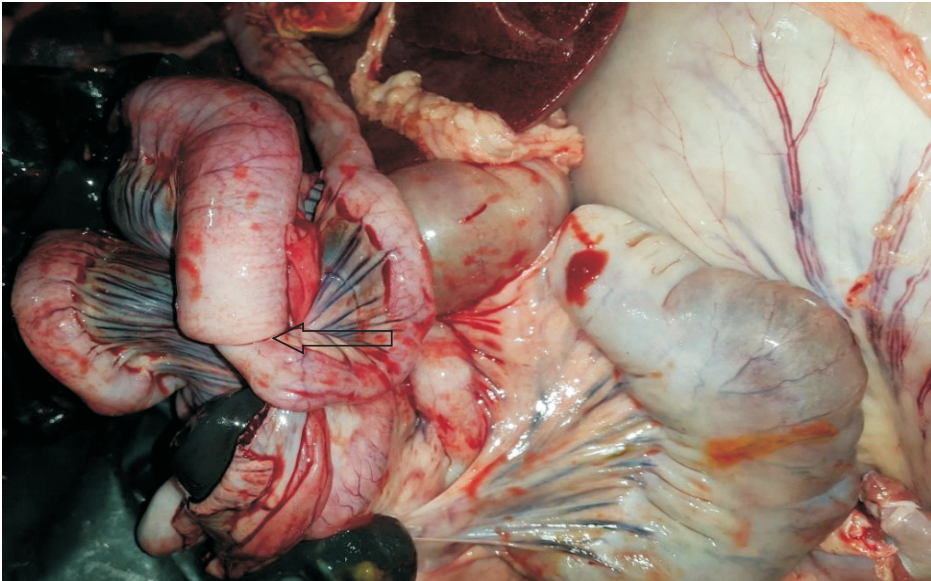


Plate 3: Small intestinal intussusception in the carcass of a Four months old American hamshire boar

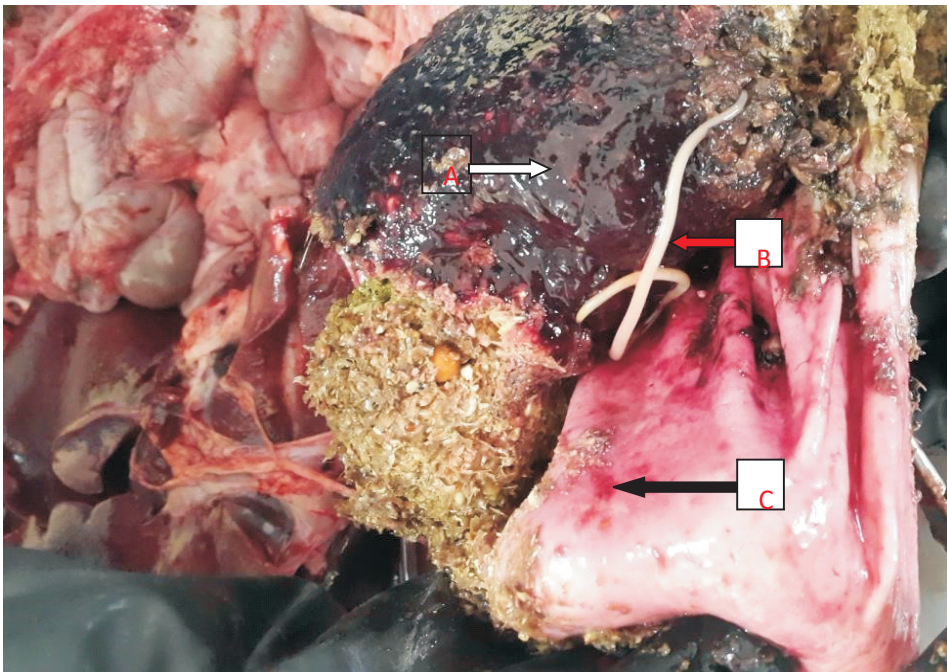


Plate 4: Tarry (blackish) colour blood (A), *Ascaris* sp. (B) and Gastric ulceration (C) in the carcass of a Four month old American hamshire boar



Plate 5: *Ascaris suum* from the stomach and small intestine carcass of a Four months old American hamphshire boar

Discussion

The 35mg of 17% piperazine adipate solution was administered orally as a single dose because of its low toxicity, availability and its effective against *Ascaris* spp (Aliu, 2011). The 700mg of 20% oxytetracycline long acting administered deep intramuscularly against secondary bacterial infections as pneumonia and enteritis are sequelae to ascariasis in pigs (Saka-kibara *et al.*, 2002; Stewart and Hoyt, 2006; Karanja *et al.*, 2011). Lack of deworming of a naive pig like this boar coupled with the persistent and resistant nature of *Ascaris* spp. eggs, the boar might have contracted it from where it was purchased or from its dam. This might have been responsible for the Ascariasis diagnosed in this case. The grossly distended stomach with ingesta was due to the mechanical blockage of the intestine by the adult *Ascaris* resulting into intussusception. The gastric ulcerations were caused by the *Ascaris* feeding habit of

attaching and detaching itself to the gastric mucosa to suck blood thereby causing the massive haemorrhage observed and which got digested in the stomach and appeared as tarry (blackish) colour.

Conclusion and recommendation

Based on the helminthology laboratory result and the post mortem findings, it was concluded that the boar died of gastric ulcers and intussusception of the small intestine due to Ascariasis.

Routine deworming and keeping records of deworming program were advocated to the farmer.

References

- Aliu, Y. O. 2011. *Piperazine*. Veterinary Pharmacology, first edition. Tamaza publishing company Ltd, No.4 Kaduna Bypass, Zaria, Nigeria. Pp. 454.
- Dold, C, Holland, C. V. 2011. *Ascaris* and ascariasis. *Microbes Infections*,

A case of gastric ulcers and intussusception due to Ascariasis

- 13:632–7
- Hale, O. M., Stewart, T. B. and Marti, O. G. 1985.** Influence of an experimental infection of *Ascaris suum* on performance of pigs. *Journal of Animal Science* 60: 220-225.
- Igbokwe, I. O. and Maduka, C. V. 2018.** Disease burden affecting pig production in Nigeria: Review of current issues and challenges. *Rev. Elev. Med. Vet. Pays Trop.*, 71 (1-2) : 1 - 9 , doi : 10.19182/remvt.31290.
- ISU -Iowa State University of Science and Technology. 2018.** College of Veterinary Medicine. 1800 Christensen Drive, Ames, Iowa 50011-1134 515-294-1242.
- Karanja D. N., Ngatia, T. A., Wabacha, J. K., Bebor, L. C., Ng'ang'a, C. J. 2011.** Pathogenic effects associated with natural gastrointestinal helminth infections in pigs in Kenya. *Bull. Anim. Health Prod. Afr.*, 59 (1): 53 - 59 , doi : 10.4314/bahpa.v59i1.68408.
- Krasnonos, L. N. 1978.** Prolonged survival of *Ascaris lumbricoides* L., 1758 ova in the soil in Samarkand. *Meditsinskaya Parazitologiya i Parazitarnye Bolezni* 47: 103–105
- Miller, L. A., Colby, K., Manning, S. E., Hoenig, D., McEvoy, E., Montgomery, S. P., Mathison, B., de Almeida, M., Bishop, H., Dasilva, A., and Sears, S. 2015.** Ascariasis in humans and pigs on small-scale farms, Maine, USA, 2010-2013. *Emerging Infectious Diseases*, 21(2): 332-334.
- Mu"ller, G. 1953.** Untersuchungen u"ber die Lebensdauer von Askarideneiern in Gartenerde. *Zentrallblatt fu"r Bakteriologie, Parasitenkunde, Infektionskrankheiten und Hygiene* 159, 377–379.
- Odile, L. and Francoise, B. 2003.** Evolution of Ascariasis in humans and pigs: a multidisciplinary approach. *Institute Oswaldo Cruz, Rio de Janeiro*, 98 (1): 39-46.
- O'Lorcaín, P. and Holland, C. V. 2000.** The public health importance of *Ascaris lumbricoides*. *Parasitology*, 121 (suppl.): S51-71.
- Saka-kibara, A., Baba, K., Niwa, S., Yagi, T., Wakayama, H., Yoshida, K., Kobayashi, T., et al., 2002.** Visceral larva migrans due to *Ascaris suum* which presented with eosinophilic pneumonia and multiple intra-hepatic lesions with severe eosinophil infiltration. Outbreak in a Japanese area other than Kyushu. *Internal Medicine*, 41 (7): 574-579, doi: 10.2169/internalmedicine.41.574
- Stephenson, L. S., Pond, W. G., Nesheim, M. C., Krook, L. P. and Crompton, D. W. T. 1980.** *Ascaris suum*: nutrient absorption, growth and intestinal pathology in young pigs experimentally infected with 15-day-old larvae. *Experimental Parasitology*, 49: 15–25.
- Stewart, T. B. and Hoyt, P. G. 2006.** Internal parasites. In: Straw, B.E., Zimmerman, J.J., D'Allaire, S., Taylor, D.J. (Eds.), *Diseases of Swine*, 9th ed. Blackwell Publishing, Ames, IA, USA, pp. 901–914.
- Worldwatch Institute. 2018.** worldwatch@worldwatch.org 1400 16th St. NW, Ste. 430, Washington, DC 20036 (202) 745-8092.
- Received: 10th September, 2018**
Accepted: 21st December, 2018