

Histopathological effect of aqueous bitter leaf extract (*Vernonia amygdalina*) on acetaminophen-induced liver damage in albino rat (*Rattus norvegicus*)

*Raimi, C. O., **Oyelade, W. A. and ***Iyanda, A. O.

* Department of Agricultural Technology, Federal Polytechnic, Ado-Ekiti, Ekiti State, Nigeria.

**Department of Sciences Technology, Federal Polytechnic, Ado-Ekiti, Ekiti State, Nigeria.



*** Department of Agricultural Technology, Federal Polytechnic, Ado-Ekiti, Ekiti State, Nigeria.

Corresponding author: *christosinr@gmail.com, Tel: +2348102256197

Abstract

Liver diseases are a worldwide problem. Medicinal plants are being increasingly utilized to treat a wide variety of diseases, liver disorder inclusive. The effect of aqueous leaf extracts of Vernonia amygdalina on acetaminophen-induced liver damage via the assessment of the histopathological examination was examined. Five groups of albino rats were used (n = 5). Animals in group 1 were fed normal laboratory pellet and water ad libitum (Control); those in group 2 received 3000mg/kg of acetaminophen alone. Groups 3, 4 and 5 received 3000mg/kg of acetaminophen and in addition 50mg/kg Vernonia amygdalina leaf extract, 100mg/kg Vernonia amygdalina leaf extract and 200mg/kg Silymarin, respectively for 14 days. Twenty-four hours after the last administration, the animals were sacrificed. The organs (liver) was excised and used for the histopathological examination. Histological examinations of the liver showed acetaminophen-induced hepatotoxicity. Histology of the liver revealed altered cellular architecture (poor architecture, moderate to severe congestion of the portal vein as well as severe peri portal infiltration of inflammatory cells, the liver parenchyma also showed area with destroyed liver plates with severe hemorrhage and necrosis. The morphology of the hepatocytes showed some degenerated liver cells, the liver parenchyma also showed focal area of moderate aggregate of inflammatory cells) following administration of acetaminophen (Group 2). Normal histological features were restored after treatment with aqueous leaf extract of Vernonia amygdalina. The study has demonstrated that aqueous leaf extract of Vernonia amygdalina ameliorate liver of rats against acetaminophen-induced toxicity and modulates the adverse effects of acetaminophen on the liver.

Key words: Albino rats, Histopathology, Liver, Acetaminophen, *Vernonia amygdalina*

Introduction

Toxicity is the extent at which a compound causes harm to animal and plant tissue or organs. It can be acute, sub chronic, or chronic. There is a wide distribution of biologically-active constituents throughout the plant kingdom, particularly in plants used as animal feeding stuff and in human nutrition. The knowledge that these compounds elicit both toxic and advantageous biological responses has

given rise to several investigations in recent times as to their possible physiological implications in various biological systems. Toxicity is expressed generally as a dose-response relationship, involving the quantity of substance to which the organism is exposed to. Furthermore, it is well known that many plant products contain some toxic substances which when consumed could accumulate gradually in the body and later cause some damages to cells, tissue or

Histopathological effect of aqueous bitter leaf extract (Vernonia amygdalina)

organs (Enujiugha, 2003). The toxic effects of environmental toxins and drugs on the human and animal system have become a major health concern (Nawal, 2015). Paracetamol (acetaminophen) as a pain killer is widely used for the treatment of mild pain and pyrexia. Paracetamol, being an analgesic has been proven to cause hepatic centrilobular necrosis when given at over dose. Da Silva Melo *et al.* (2016) reported that paracetamol (acetaminophen), an over-the-counter drug, is widely used for the treatment of mild pain and pyrexia. Because of its over-the-counter status, cases of both accidental and intentional paracetamol (APAP) overdose are numerous. As a result of this high rate of abuse, paracetamol has been described by Larson *et al.* (2010) as the most common cause of drug induced liver failure in the United States. At overdose level, paracetamol causes hepatic centrilobular necrosis (James *et al.*, 2014) which has been linked to excessive generation of N-acetyl-p-benzoquinoneimine (NAPQI). It had been observed that mitochondria may be the primary targets in acetaminophen (APAP) toxicity with particular attention on the mitochondrial permeability transition. Involvement of other generated reactive oxygen species such as nitric oxide and superoxide anion cannot also be discounted in paracetamol-induced hepatocyte death (Chang and Trivedi, 2014). A number of antidotes had been suggested for the treatment of APAP-induced liver damage, one of which is *Vernonia amygdalina*. *Vernonia amygdalina* is well known as a medicinal plant with several uses attributed to it, including for diabetes, fever reduction, and recently a non-pharmaceutical solution to persistent fever, headache, and joint pain associated with AIDS (Ohigashi *et al.*, 2010). These leaves are exported from several African countries. The roots of *V. amygdalina* have been used for gingivitis

and toothache due to its proven antimicrobial activity (Jisaka *et al.*, 2012). *Vernonia amygdalina* (compositae) is a small shrub that grows predominantly in the tropical Africa. In Nigeria, the plant is locally called bitter leaf due to its bitter taste. The macerated leaves of the plant are used in making soup while the water extract serves as a tonic drink. In the local community, the leaves are used as anthelmintic, a laxative and an antimalarial because they contain quinine substitute. It is noted that the leaves contain stigmastane-type saponin such as vernoniosides A1, B1, A2, A3, B2, D2, A4 and C which have been identified in the leaves (Jisaka *et al.*, 2012). Earlier investigation on *Vernonia amygdalina* showed that purified chloroform fractions identified as vernodaline, vernolide and vernomygdine elicited cytotoxic effects in human carcinoma involving nasopharynx cells with IC50 values of 1.8, 2.0 and 1.5 =g/ml respectively. It was concluded that the activities were dependent on their possession of the (alphamethyl- gamma-lactone group) as their structures (Jisaka *et al.*, 2012). For years now since the discovery of *Vernonia amygdalina* there has been a store of information on the clinical value of this plant. However less than 10% of the world's flora had been studied chemically in detail to determine their active constituents; phytochemical components and histopathological effects of this plant when consumed (Yang and Health, 2014). Silymarin (extracted from the seeds of *Silybum marianum* or milk thistle) can also be used in the treatment of liver diseases. Silymarin may be of use as an adjuvant in the therapy of alcoholic liver disease. This study revealed the histopathological effect of *Vernonia amygdalina* and Silymarin on acetaminophen-induced liver damage in albino rat (*Rattus norvegicus*) concurrently administered with toxic doses of

paracetamol.

Materials and methods

Study area

The study was carried out at the Animal Production unit, Department of Agricultural Technology, Federal Polytechnic, Ado-Ekiti, Ekiti State, Nigeria.

Plant materials

Samples of Bitter leaf (*Vernonia amygdalina*) were obtained from a private farm in Ado Ekiti, air dried in the laboratory, pulverized and then stored in an airtight container.

Reagents and chemicals

All reagents and chemicals were all of analytical grade

Preparation of bitter leaf extract

Vernonia amygdalina were air-dried for 30 days at room temperature. The air-dried samples were ground to fine powder using a blender. The powdered leaf (500g) was soaked in 2000 ml of distilled water for 72 hours. It was then filtered using a cheese cloth, and freeze-dried to obtain the dried

extract. The extract was kept in a closed container and kept inside the fridge at 4°C for further studies.

Plant materials

Fresh Bitter leaves (*Vernonia amygdalina*) were collected from a private farm in Ado Ekiti Ado Ekiti Local Government Area of Ekiti State, Nigeria, Botanical Identification and authentication was carried out at the Department of Biological Sciences, Federal Polytechnic, Ado Ekiti.

Experimental animals

A total of twenty five male (25) Wistar albino rats weighing 150 g –170 g were obtained from a reputable farm in Ado Ekiti and were housed in clean wire meshed cages under standard conditions temperature (24 ± 1°C), relative humidity, and 12/12-hour light and dark cycle. They were acclimatized for two weeks under standard environmental conditions and maintained on a regular feed and water *ad libitum*. They were allowed free access to commercial pelletized diets daily. The rat beddings were changed every day throughout the experimental period.

Experimental design

Groups	Treatment
Group 1: Normal control (NC)	Distilled water only for 14 days
Group 2: Induced untreated group (Positive Control)	3000mg/kg acetaminophen alone for a single administration
Group 3	3000mg/kg acetaminophen + 50 mg/kg <i>Vernonia amygdalina</i> extract for 14 days
Group 4	3000mg/kg acetaminophen + 100 mg/kg <i>Vernonia amygdalina</i> extract for 14 days
Group 5	3000mg/kg acetaminophen + 200 mg/kg Silymarin for 14 days

Dissection of rats

The rats were dissected and liver was excised using scissors and forceps, washed in distilled water, blotted with filter paper and weighed.

Histopathological analysis

Histopathological Analysis was carried out

according to the method of Avwioro (2010).

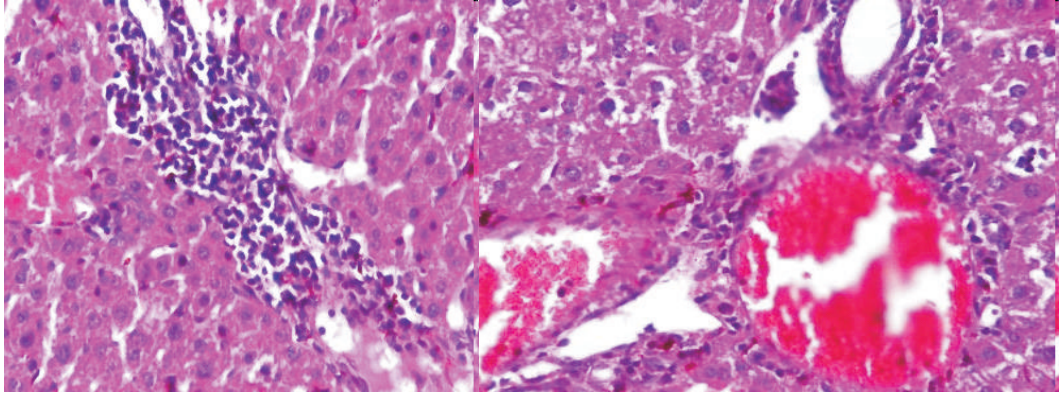
Results

The photomicrograph of the liver of experimental animals showed a high power magnification (x400mag) of the hepatocytes. Photomicrographs showed the

Histopathological effect of aqueous bitter leaf extract (Vernonia amygdalina)

architecture and histo-morphological manifestation of the hepatocytes.

Positive Control (Induced Untreated Group)

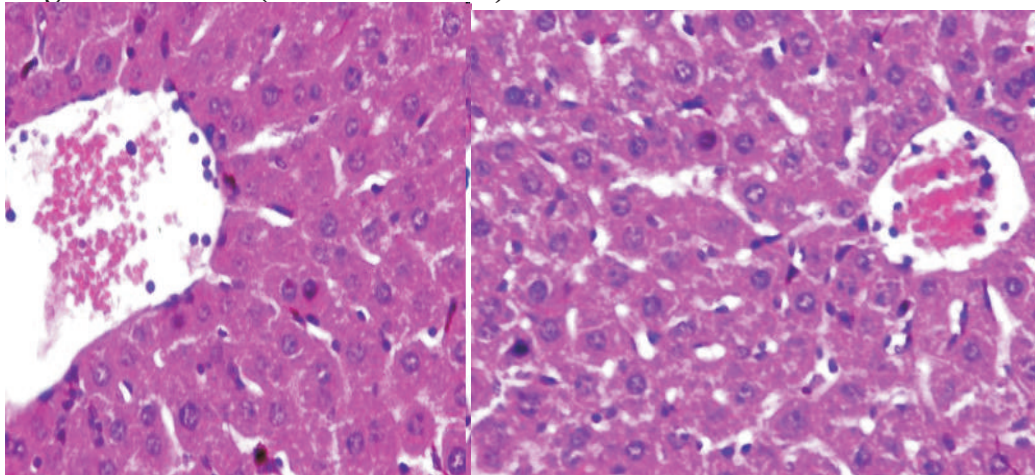


LIVER (X400)

Photomicrograph of a liver section stained by Haematoxylin and Eosin showed poor architecture, there was moderate to severe congestion of the portal vein (white arrow) as well as severe peri portal infiltration of inflammatory cells (black arrow), the liver parenchyma also showed

area with destroyed liver plates with severe hemorrhage and necrosis (green arrow), the morphology of the hepatocytes showed degenerated liver cells (blue arrow), the liver parenchyma also showed focal area of moderate aggregate of inflammatory cells, the sinusoids appear normal and not infiltrated (slender arrow).

Negative Control (Normal Control)

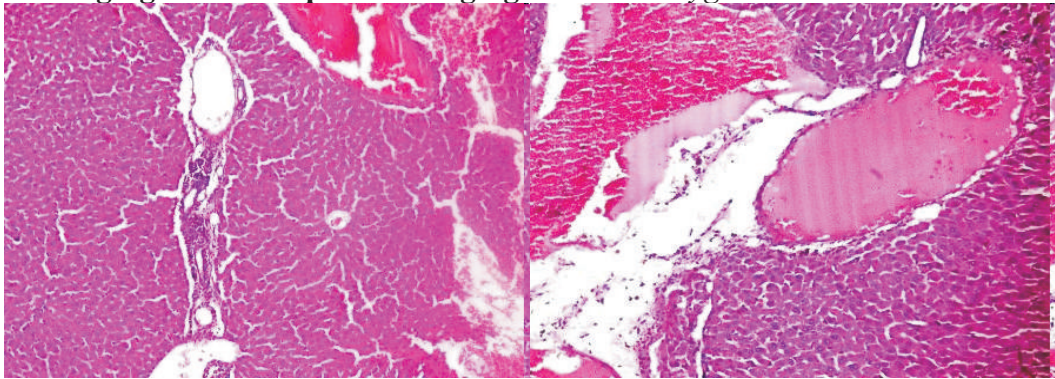


LIVER: Normal liver tissue (X400)

Photomicrograph of a liver section stained by Haematoxylin and Eosin showed normal central venules without congestion (white arrow), the morphology of the hepatocytes

appeared normal (blue arrow), the sinusoids appeared normal and not infiltrated (slender arrow), no pathological lesion seen.

3000mg/kg acetaminophen +50mg/kg *Vernonia amygdalina*

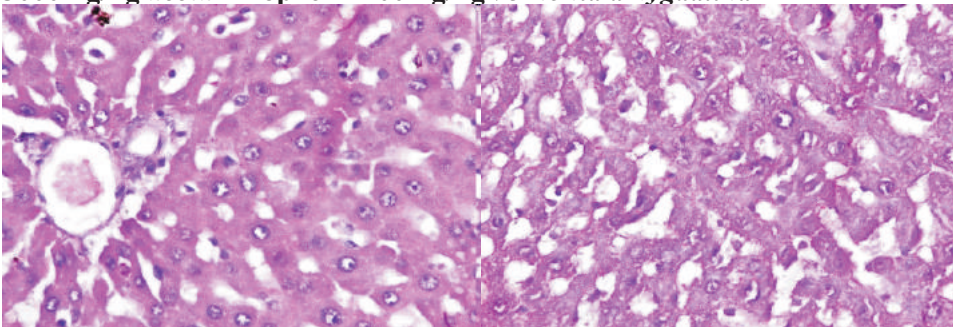


LIVER (X400)

Photomicrograph of a liver section stained by Haematoxylin and Eosin showing poor architecture, there was moderate to severe congestion of the portal vein (white

arrow) as well as severe peri portal infiltration of inflammatory cells (black arrow) and the morphology of the hepatocytes show some degenerated liver cells (green arrow).

3000mg/kg acetaminophen +100mg/kg *Vernonia amygdalina*

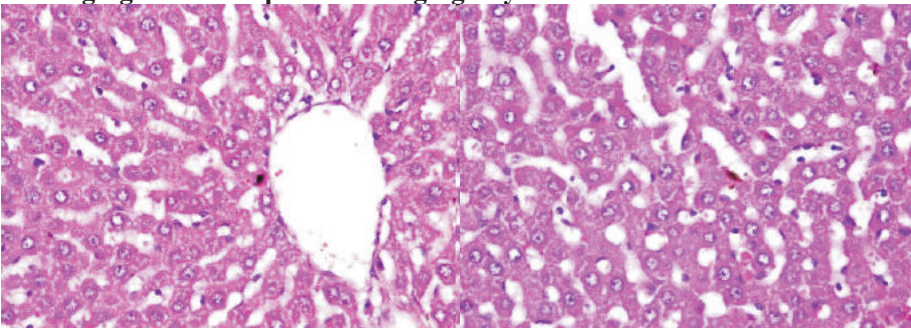


LIVER (X400)

Photomicrograph of a liver section stained by Haematoxylin and Eosin showed normal central venules (white arrow), the

morphology of the hepatocytes appear normal (blue arrow), the sinusoids appear normal and not infiltrated (slender arrow), no pathological lesion seen.

3000mg/kg acetaminophen +200mg/kg Silymarin



LIVER: normal liver tissue (X400)

Histopathological effect of aqueous bitter leaf extract (Vernonia amygdalina)

Photomicrograph of a liver section stained by Haematoxylin and Eosin showing normal central venules and portal tract without congestion (white arrow), the morphology of the hepatocytes appear normal (blue arrow), the sinusoids appear normal and not infiltrated (slender arrow), no pathological lesion seen.

Discussion

Histopathological changes of the liver tissue manifesting as, hepatocellular necrosis and lymphocytes infiltration are indicative of hepatotoxicity (Nabeshima *et al.*, 2012). Severe histoarchitectural distortion of the liver parenchyma observed as diffused necrosis of hepatocytes, infiltration of the inflammatory cells and congestion of the portal vein in the liver section of Wistar rats treated with acetaminophen only when compared with the liver sections of the control is indicative of acetaminophen related hepatotoxicity. Necrosis is a type of cell death that occurs after abnormal stresses such as chemical injury or toxin. Necrotic cells are unable to maintain membrane integrity as they leak out their content and this may elicit inflammation in the surrounding tissue (Kumar *et al.*, 2010). This result is in accordance with reports on CCl₄ administration namely, loss of the normal liver histo-architecture and cyto-architecture (Soufy *et al.*, 2012). Inflammation is a protective response, the ultimate goal, which is to get rid of the initial cause of the cell injury (e.g., acetaminophen, toxin; CCl₄) and the consequence of such injury (necrotic cells and tissues) (Kumar *et al.*, 2010). Histo-architectural distortion, such as, infiltration of inflammatory cells and congestion, a local increase in the volume of blood as a consequence of impaired outflow from the hepatic tissue, were observed in the liver section of rats treated with acetaminophen. Histopathological changes were, however,

mild in group treated with 50mg/kg *Vernonia amygdalina* when compared with the liver sections of the group administered acetaminophen only as the cyto-architecture of the liver parenchyma was preserved. Treatment with *Vernonia amygdalina* at 50 mg/kg followed by the administration of acetaminophen revealed histo-architectural preservation of the liver parenchyma against acetaminophen intoxication manifesting as mild histopathological changes when compared with the severely damaged liver sections of acetaminophen-treated group. Administration of the extract *Vernonia amygdalina* at 100 mg/kg dose and Silymarin at 200mg/kg dose improved the histo-architecture of the liver and by extension restored its functionality. The groups administered with *Vernonia amygdalina* at (100 mg/kg) dose and Silymarin at (200mg/kg) dose demonstrated a distinct regenerative capacity over the other 50mg/kg *Vernonia amygdalina* extract. Histoarchitectural distortion, such as, hepatocellular necrosis, central vein congestion and inflammatory cells infiltration observed in the liver sections is resultant of acetaminophen intoxication, while observed histoarchitectural preservation is consequent to treatment with plant extract *Vernonia amygdalina* at 100 mg/kg and silymarin at 200mg/kg. This finding is supportive of medicinal plant related studies that have reported hepatoprotective activity of plant extracts; (Al-Qarawi *et al.*, 2012) treatment with plant extract decrease the severity of histopathological changes induced by CCl₄. Silymarin is a well-established hepatoprotective drug and used as a reference drug for comparison of hepatoprotective activity of plants principle (Pradhan *et al.*, 2011). The ability of Silymarin in preventing drug induced hepatotoxicity is associated with its ability to act as a radical scavenger, thereby

protecting membrane permeability (Song *et al.*, 2016). Extract *Vernonia amygdalina* at (100 mg/kg) dose presented histoarchitectural preservation of the liver parenchyma when compared with the standard drug, Silymarin-treated group. Treatment 100mg/kg dose demonstrated the plant extract potentials as a free radical scavenger and lipid peroxidation inhibitor, thus helping to maintain the integrity and permeability of cell membranes and protects cells and tissues against oxidative stress induced by free radicals (Naik *et al.*, 2017).

Conclusion and Recommendation

The result of this study suggested that *Vernonia amygdalina* was effective histologically in preventing acetaminophen-induced acute liver injury in Wistar rats, especially at dose of 100 mg/kg body weight. The hepatoprotective activity of the plant extract which could be of therapeutic potentials might be consequent to the antioxidant activities of constituent phytochemicals. Therefore, it is recommended that extract of *Vernonia amygdalina* can act as an adjunct in chronic treatment of liver injury.

References

- Al-Qarawi, A., Mousa, H. M., Ali, B. H., Abdel-Rahman, H. and El-Mougy, S. A. 2012. Protective effect of extracts from dates (*Phoenix dactylifera* L.) on carbon tetrachloride-induced hepatotoxicity in rats. *Int J Appl Res Vet M*, 2:176-80.
- Avwioro, O. G. 2010. Histochemistry and tissue pathology, principle and techniques, Claverianum press, Nigeria.
- Chang, F. R. and Trivedi, P. K. 2014. Economics of self-medication: Theory and evidence. *Health Econ* 12 (9):721-39.
- Da Silva, Melo, D. A., Saciura, V. C., Poloni, J. A., Oliveira, C. S., Filho, J. C., Padiha, R. Z., Reichel, C. L., Neto, E. J., Oliveria, R. M., D'avila, C., Kessler, A. and de Oliveira, J. R. 2016. Evaluation of renal enzymuria and cellular excretion as marker of acute nephrotoxicity due to an overdose of paracetamol in Wistar rats. *Clin. Chim. Acta.* 373(1-2):88-91.
- Enujiugha, V. N. 2003. Chemical and functional characteristics of Conophor nut. Pakistan *Journal of Nutrition.* 2:335-338.
- James, L. P., Berhe, A. H., Hadera, M. G. 2014. Self-medication practices among health sciences students: The case of Mekelle University. *J Appl Pharm Sci* 12):13-20.
- Jisaka, M., Ohigashi, H., Takagaki, N., Tada, T. and Hirota, M. 2012. Bitter steroid glycosides, vernoniosides A1, A2, A3 and B1 from *Vernonia amygdalina* used by wild chimpanzee. *Tetrahedron.* 48. 625-663.
- Kumar, V., Alla, S. R., Krishnan, K. S. and Ramaswami, M. 2010. Syndapin is dispensable for synaptic vesicle endocytosis at the Drosophila larval neuromuscular junction. *Mol Cell Neurosci*40:234-41.
- Larson, A. M., Polson, J., Fontana, R. J., Davern, T. J., Lalani, E., Hynan, L. S., Reisch, J. S., Schiodt, F. V., Ostapowicz, G., Shaki, A. O. and Lee, W. M. 2010. Acetaminophen sets record in the United States: Number 1 analgesic and number 1 cause of acute liver failure. *Hepatology.* 42:1364-1372.
- Liu, F., Mahmood, M., Xu, Y., Watanabe, F. and Biris, A. S. 2015. Effects of

- silver nanoparticles on human and rat embryonic neural stem cells. *Frontiers Neurosci.*, Vol. 9. 10.3389/fnins.2015.00115
- Nabeshima, Y., Tazuma, S., Kanno, K., Hyogo, H., Iwai, M., Horiuchi, M. 2012.** Anti-fibrogenic function of angiotensin II type 2 receptor in CCl₄ -induced liver fibrosis. *Biochem Biophys Res Commun* 346:658-64.
- Naik, S. R. and Panda, V. S. 2012.** Antioxidant and hepatoprotective effects of Ginkgo bilobaphytosomes in carbon tetrachloride-induced liver injury in rodents. *Liver Int* 27:393-9.
- Nawal, K. A., Ula, A. K., Ban, T. S. 2015.** Protective influence of zinc on reproductive parameters in male rat treated with cadmium. *Am J Med Med Sci* 5:73-81
- Ohigashi, H., Jisaka, M., Takagaki, N., Tada, H. and Nishida, T. 2010.** A bitter principle and related steroid glycoside of vernoniaamygdalina, a possible medical plant for wild chimpanzee. *Agric and biological chemistry.* 55 (5):1201- 1203.
- Pradhan, S. C. and Girish, C. 2011.** Hepatoprotective herbal drug, Silymarin from experimental pharmacology to clinical medicine. *Indian J Med Res* 124:491-504
- Rajesh, S. V., Raj Kapoor, B., Kumar, R. S. and Raju, K. 2010.** Effect of Clausenadentata (Willd.) M. Roem. against paracetamol induced hepatotoxicity in rats. *Pak J Pharm Sci.* 22(1):90-3.
- Reid, A. B., Kurten, R. C., McCullough, S. S., Brock, R. W. and Hinson, J. A. 2010.** Mechanisms of acetaminophen-induced hepatotoxicity: role of oxidative stress and mitochondrial permeability transition in freshly isolated mouse hepatocytes. *J. Pharmacol. Exp. Ther.* 312:509-516.
- Song, Z., Deaciuc, I., Song, M., Lee, D. Y., Liu, Y., Ji X, et al 2016.** Silymarin protects against acute ethanol-induced hepatotoxicity in mice. *Alcohol Clin Exp Res* 30:407-13.
- Soufy, N. I. 2012.** Hepatoprotective and antioxidant effects of *Silybummarianum* plant against hepatotoxicity induced by carbon tetrachloride in rats. *J Am Sci* 8:479-786.
- Talebi, K. H., Hosseinaveh, V. and Ghadamyari, M. 2011.** Ecological Impacts of Pesticides in Agricultural Ecosystem. In: *Pesticides in the Modern World-Risks and Benefits*, Stoytcheva, M. (Ed.). In Tech Open Access Publisher, Rijeka, Croatia, pp: 143-169.
- Yang, B. and Health, J. 2014.** *Phytochemical screening.* 3rd ed. San Francisco. McGraw Hill Companies. 342-372.
- Zarkovic, K., Kolenc, D., Coric, M., Brcic, L., Klicek, R., Radic, S. M., Djuzel, V., Ivica, M., BobanBlagaic, A., Zoricic, Z., Anic, T., Zoricic, I., Djidic, S., Romc, Z., Seiwert, S. and Sikiric, P. 2010.** High hepatotoxic dose of paracetamol produces generalized convulsions and brain damage in rats. A counteraction with the stable gastric pentadecapeptide BPC 157 (PL 14736)

Received: 20th June, 2020

Accepted: 29th September, 2020